

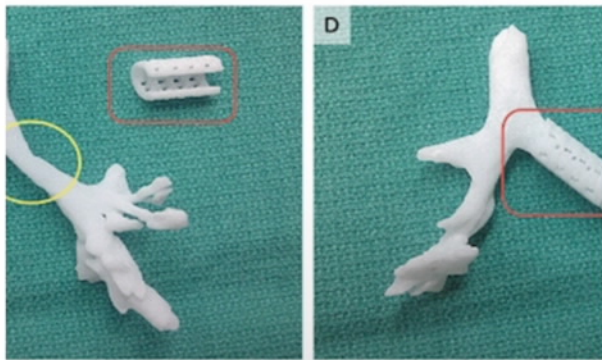
医疗的颠覆性创新— 医学信息学的启示

OVID 潘群

2014年5月14日 哈尔滨工业大学

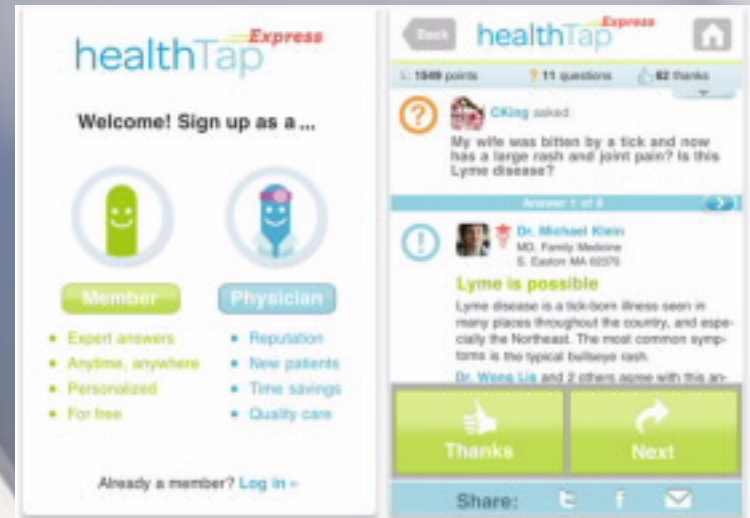


医疗事业的新发展



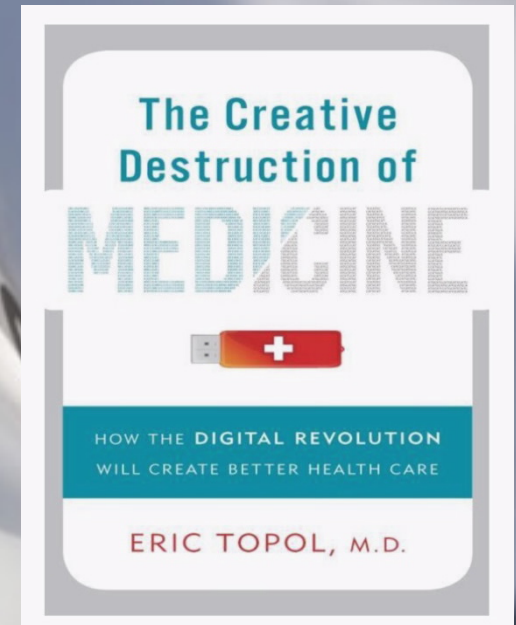
经由: Engadget

引用来源: Gizmodo、New England Journal of Medicine



“In the mid-twentieth century Joseph Schumpeter, the noted Austrian economist, popularized the term “creative destruction” to denote transformation that accompanies radical innovation. In recent years, our world has been “Schumpetered.”

颠覆性创新



医疗个性化的变革正在发生

- 正如社交媒体推动的许多个性化变革, 医疗正在从大众化向个性化, 多样化发展
- 基因测序的门槛降低…
- 个体的身体及疾病数据收集…
- *“There is one theme, one reason, why this creative destruction is ready to go. It is because for the first time in history we can digitize humans. You know about digitizing pictures and information like books, newspapers, and magazines. It seems that everything now is digitized and widely transferable. You can download a two-hour movie in seconds. But that is a world apart from digitizing a human being.” (Excerpt From: Eric Topol M. D. “The Creative Destruction of Medicine: How the Digital Revolution Will Create Better Health Care.”) (人体数字化是重要的历史进步)*

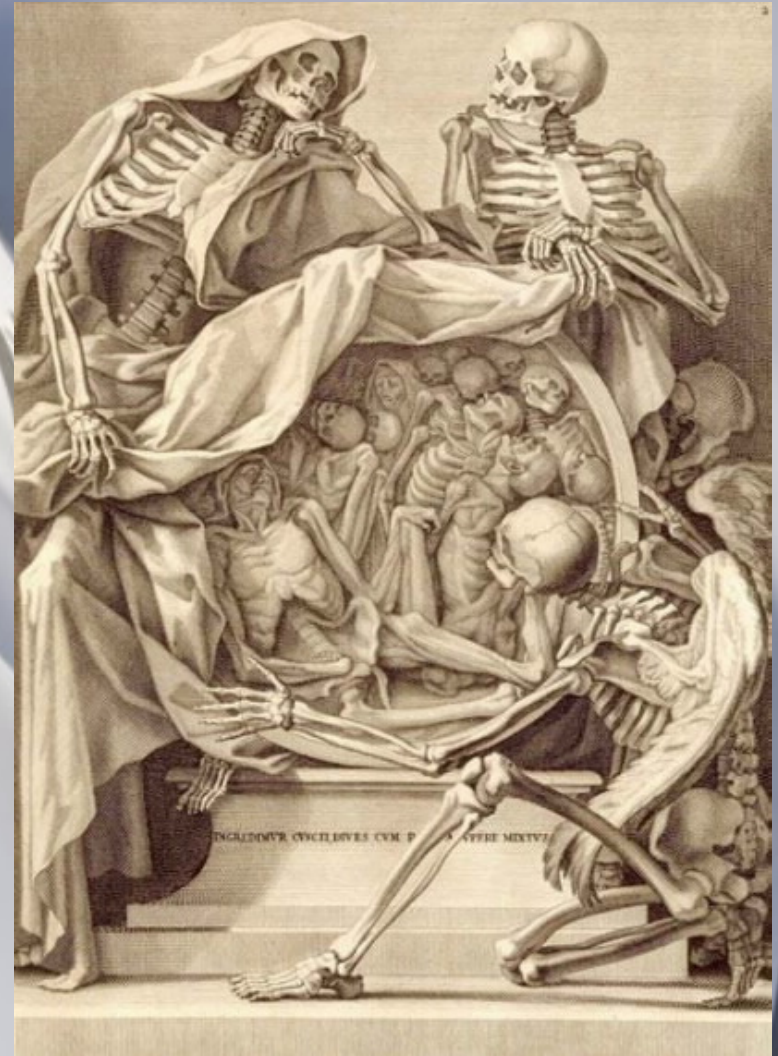医学教育和科研如何面对新的挑战？

- 当今医学已不像以往那么单一，它的模式集预防，预测，个性化治疗和适宜技术治疗于一体…（复旦大学 冯晓源）
- 医学教学和科研更加多元，交叉…
- 在过去的30年，影像医学俨然成为了交叉学科的基础。没有一个领域的科学象影像医学那样整合了物理学和计算机科学并把它们成功地与本学科快速地结合在一起 (Dr. Elias A. Zerhouni)
- 仅仅依赖获取文本文献远远不够…





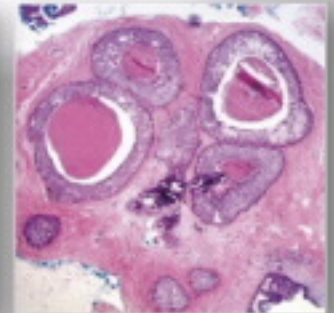
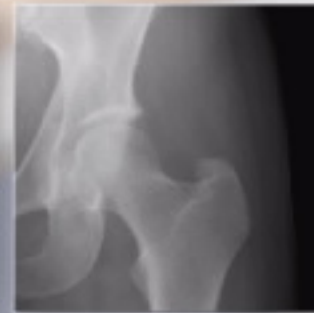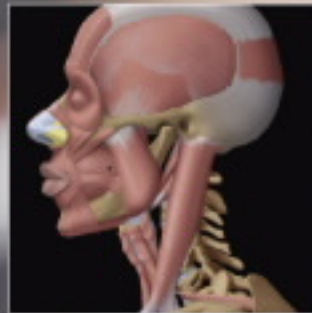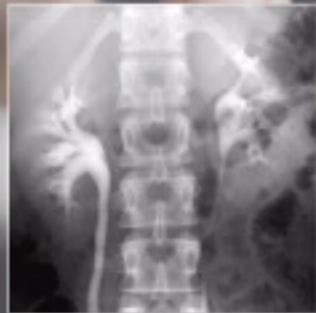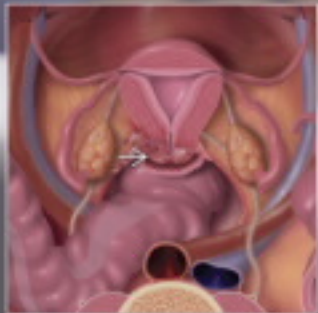OVID医学影像





AMIRSYS[®]

The Authority in Radiology,
Pathology, and Anatomy.





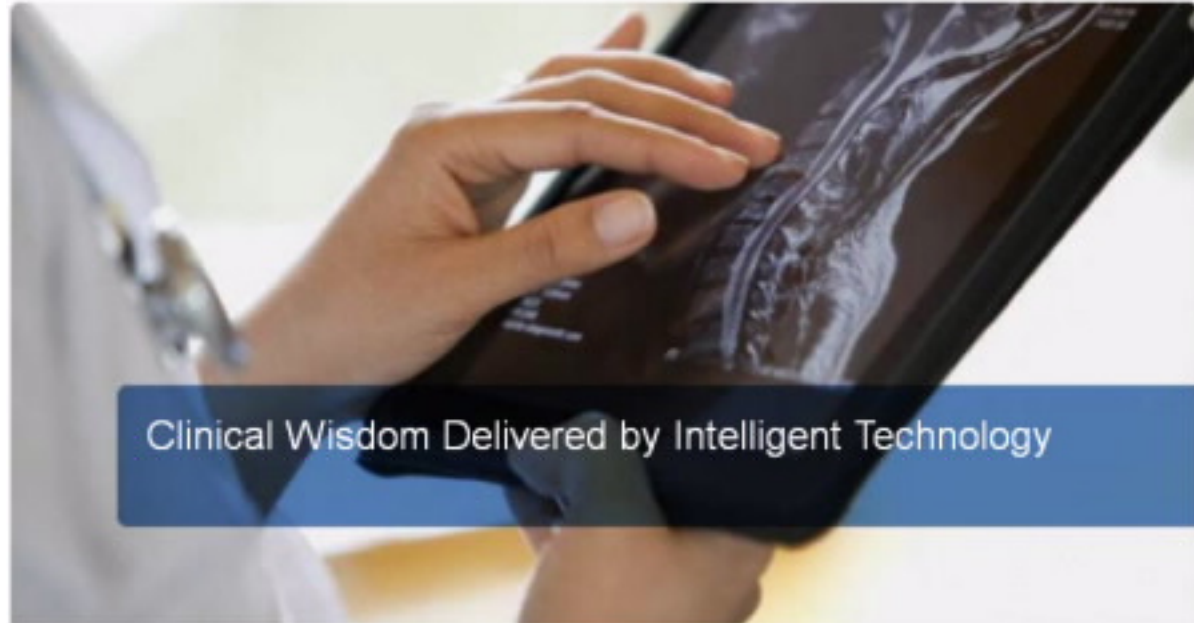Meet Amirsys

Amirsys是谁？

全球顶尖的放射医学，
病理学，解剖学的医疗
出版社及信息提供商。

源自犹他州大学医学院

与美军病理研究所的渊
源



Amirsys, Inc.

- Ric Harnsberger, MD Co-CEO
- Paul Scholtes, JD,MS,MS Co-CEO
- Julia Sherman, RPh EVP

Amirsys Publishing, Inc.

- Anne Osborn, MD CEO
- Paula Woodward, MD President



Online **radiology**,
pathology, and **anatomy**
references for the whole institution.



Imaging Reference Center

Imaging references for a wide range of medical specialties and health professionals.

- Comprehensive: 4,000 classic imaging diagnoses
- Image Rich: 72,000 x-ray, CT, MR, ultrasound, full-color graphics, and clinical photographs
- Expert Content: Written by imaging experts, supported by over 40,000 journal references

[MORE INFORMATION](#)



Pathology Reference Center

Diagnostic pathology references for the whole institution.

- Comprehensive: Over 2,100 diagnoses in all areas of diagnostic pathology
- Image Rich: 36,000 gross pathology, H&E, IHC stains, correlative images, and colored graphics
- Expert Content: Written by pathology experts, supported by thousands of journal references

[MORE INFORMATION](#)



Anatomy Reference Center

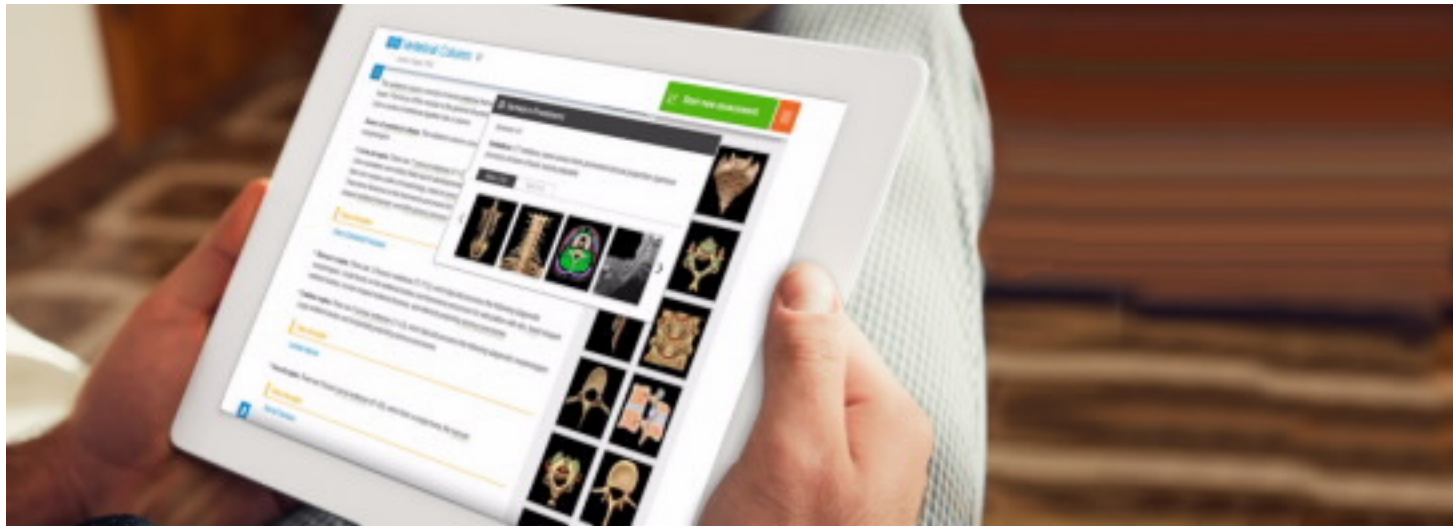Anatomy references for physicians, clinicians, and students.


- Comprehensive: Gross and imaging anatomy with 15,000 anatomy structures, spaces, and locations
- Image Rich: Highly annotated illustrations, cadaver photos, radiology images, and histology images
- Expert Content: Written by anatomy and radiology specialists

[MORE INFORMATION](#)

简明, 实用, 专业

“每一主題都是由國際知名的學者執筆而成。這些專家根據身體各主要部位而選出最常見的診斷及處理步驟，並列出重點以及高解析度的影像來表達不同的主題。同時也摘錄了主要的參考材料，供讀者作進一步研究之用。影像以全彩色的解剖病理學電腦畫像來描繪真實的案例。本系列皆以相同的格式編著。由於同類型資訊在相同的位置，讀者可以快速地自重點找到影像發現、鑑別診斷、病理學、病理生理學及有關的臨床資訊”





Amirsys 影像参考中心

平台特点

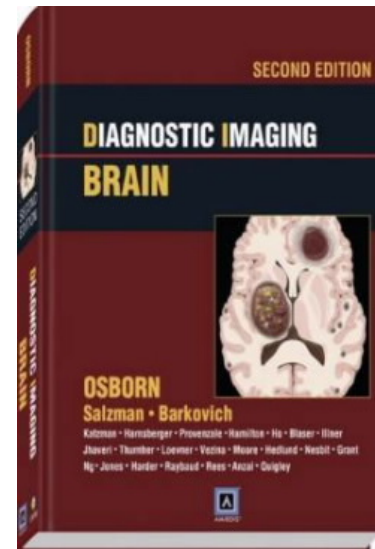
- 简明的项目符号格式, 帮助医疗专业人员有效地吸收信息
- 使用关键字来搜索所有4000诊断
- 检索结果告诉诊断类别, 在诊断参考里的包含的图像数据, 描述性文本, 和作者
- 诊断的参考文本和图像打印
- 图片下载到PPT演示稿可快速演示创建任何的影像诊断

它的内容是从哪里来的

- 对于Amirsys来说内容和图像是专有的, 他们拥有包含数据库在内的所有的图片和内容的版权.
- Amirsys的内容是由全球团队超过300位领先的放射学家, 病理学家和解剖学家创作。临床诊断的主题是由在这个特定领域的专家编写, 他们覆盖了来自全球范围的放射科医师。主题包括了超过40,000杂志文献并可链接到PubMed。

Amirsys 图像参考中心

- 超过4,000个由专家编写的实证性诊断主题
- 超过70,000个具有代表性的 X-射线、CT、MRI、超声、全色彩图示和照片
- 由图像专家提供的、由专家编写的临床内容并由超过40,000份期刊文献提供支持



Amirsys 解剖学影像参考

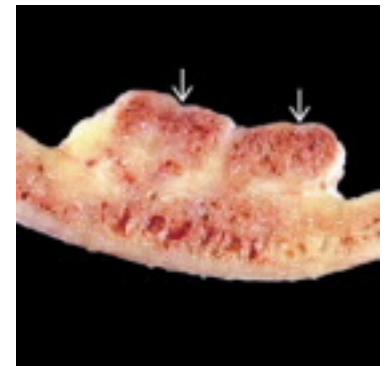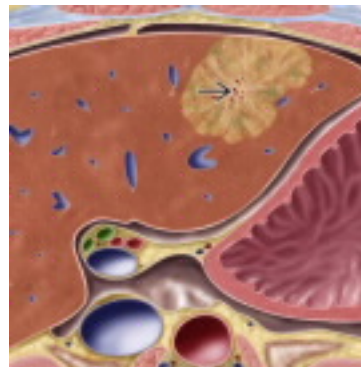


Amirsys 解剖学参考中心

- 整合所有由金牌解剖学专家和放射学专家和教育工作者编写的解剖学和图像解剖学信息
- 成千上万个高质量的专利图像：插图、大体照片、放射学图像和组织学图像，代表15,000个结构、间隙和部位
- 超过175个模块覆盖整个身体系统；90多个模块完整覆盖整个人体各部位
- 普通图像解剖学-包括CT、MRI、正常影像和超声波－针对人体各部位

Amirsys Anatomy Reference Center 覆盖所有主要的器官系统和解剖结构：

- 系统评价
- 大脑
- 肌骨系统
- 血管系统
- 腹部
- 胸部
- 神经系统 ...

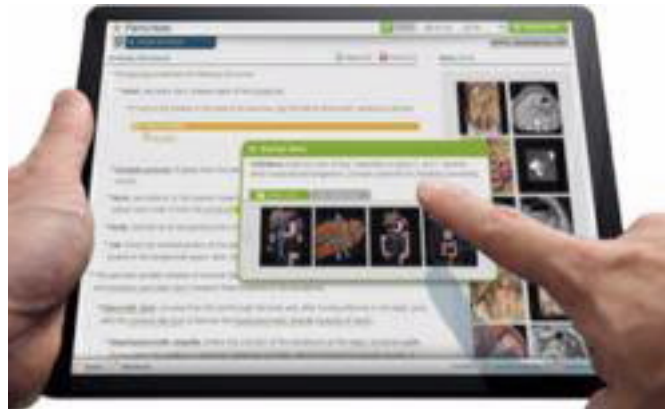

Amirsys 病理学影像参考



Amirsys 病理学参考中心

- 超过2,100个由期刊文献支持的实证性诊断
- 将近36,000个图像：普通病理学、H & E、IHC 着色、关联图像以及更多
- 主题包含摘要表格、免疫组织化学列表、染色类型和不同诊断的重点比较



Amirsys 病理学影像参考



Back to search results for "squamous cell carcinoma"

Squamous Cell Carcinoma

Author: Bruce M. Wenig, MD

Key Facts

- Key Facts**
- Terminology**
- Etiology/Pathogenesis**
- Clinical Issues**
- Image Findings**
- Macroscopic Features**
- Microscopic Pathology**
- Ancillary Tests**
- Differential Diagnosis**
- Selected References**

Cellular neoplasm arising from surface epithelium with differentiation

Factors include

Occupation, exposure to textile dust, tobacco smoking, prior use

Common sinonasal (schneiderian) papilloma; majority transform to SCC

Approximately 3% of head and neck malignant neoplasms arising order of frequency

Sinonasal sinus antrum > nasal cavity > ethmoid sinus > sphenoid, frontal sinuses

Microscopic Features

- Divided into keratinizing and nonkeratinizing subtypes
- Keratinizing squamous cell carcinoma**
 - Most common type representing 80-85% of all cases
 - Divided into well-, moderately, poorly differentiated carcinomas
- Nonkeratinizing squamous cell carcinoma**
 - Represents approximately 15-20% of all cases
 - Often shows downward (inverted or endophytic) growth with broad interconnecting bands or nests of neoplastic epithelium
 - Composed of elongated cells with cylindrical or columnar appearance

Terminology

Abbreviations

- Squamous cell carcinoma (SCC)

Synonyms

- For keratinizing squamous cell carcinoma
 - Sinonasal carcinoma
 - Epidermoid carcinoma
- For nonkeratinizing squamous cell carcinoma
 - Transitional carcinoma
 - Respiratory epithelial carcinoma
 - Ringertz carcinoma

License agreement

Squamous Cell Carcinoma

Microscopic Features (6)

Fig. 1 Fig. 2 Fig. 3 Fig. 4 Fig. 5 Fig. 6

The neoplastic epithelium is nonkeratinizing and may show cystic change

© 2013 Amirsys, Inc. All rights reserved.

Amirsys - 国际知名的作者队伍



Acland Anatomy Online

ACLAND'S VIDEO ATLAS OF
HUMAN ANATOMY



Acland 解剖视频库

Inspired Learners Can Do
Amazing Things





Wolters Kluwer
Health

Inspired Learning For Life


Lippincott Williams & Wilkins

AclandAnatomy.com (新鲜的人体标本)



AclandAnatomy.com

(全球首例内耳解剖视频影像)



Wolters Kluwer
Health

Inspired Learning For Life

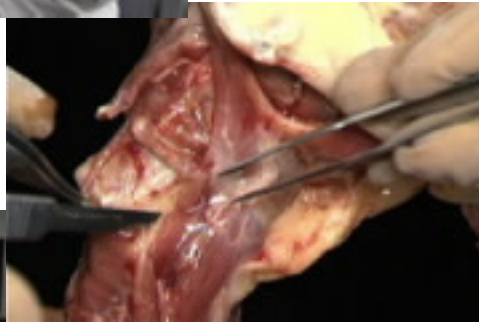Lippincott Williams & Wilkins

AclandAnatomy.com

AclandAnatomy背后的故事

■ Dr Robert D. Acland, FRCS

- University of Louisville School of Medicine, 临床解剖学家, 显微外科学家
- 花费11,000个小时制作(24小时 x 450天)
- 平均每分钟视频背后, 要花费12小时制作
- 采用先进的解剖视频录像技术



AclandAnatomy.com

真实的3D解剖!

- AclandAnatomy.com是什么样的产品?
 - 专家解剖, 真实尸体标本, 3D视频录像 - 完全如同真实活体
 - 按解剖部位分类, 328 段有讲解的视频
 - [上肢](#)
 - [下肢](#)
 - [躯干](#)
 - [头颈](#)
 - [脏器](#)
 - 总共15小时的录像(900分钟) - 无与伦比的解剖实效



AclandAnatomy.com

真实的3D解剖!

■ 特点

- 新鲜人体标本、自然的色泽(在低温房间内摄像, 标本未使用福尔马林浸泡)- 真实的质感
- 真实的解剖效果
- 从骨骼、肌肉到皮肤, 层次分明的解剖结构
- 清晰地揭示运动与空间关系
- 学生可以随时预习、复习
- 移动性 - 可以使用智能手机、平板电脑随时随地访问



